

# Accuracy and Complications Using Computer-Designed Stereolithographic Surgical Guides for Oral Rehabilitation by Means of Dental Implants: A Review of the Literature

Jan D'haese, DDS, MSc;<sup>\*†</sup> Tommie Van De Velde, DDS, MSc, PhD;<sup>†</sup> Ai Komiyama, DDS;<sup>‡</sup> Margaretha Hultin, DDS, PhD;<sup>‡</sup> Hugo De Bruyn, DDS, MSc, PhD<sup>†</sup>

---

## ABSTRACT

*Background:* In the last decade several stereolithographic guided surgery systems were introduced to the market. In this context, scientific information regarding accuracy of implant placement and surgical and prosthodontical complications is highly relevant as it provides evidence to implement this surgical technique in a clinical setting.

*Purpose:* To review data on accuracy and surgical and prosthodontical complications using stereolithographical surgical guides for implant rehabilitation.

*Material and Methods:* PubMed database was searched using the following keywords: “three dimensional imaging,” “image based surgery,” “flapless guided surgery,” “customized drill guides,” “computer assisted surgery,” “surgical template,” and “stereolithography.” Only papers in English were selected. Additional references found through reading of selected papers completed the list.

*Results:* In total 31 papers were selected. Ten reported deviations between the preoperative implant planning and the postoperative implant locations. One in vitro study reported a mean apical deviation of 1.0 mm, three ex vivo studies a mean apical deviation ranging between 0.6 and 1.2 mm. In six in vivo studies an apical deviation between 0.95 and 4.5 mm was found. Six papers reported on complications amounting to 42% of the cases when stereolithographic guided surgery was combined with immediate loading.

*Conclusion:* Substantial deviations in three-dimensional directions are found between virtual planning and actually obtained implant position. This finding and additionally reported postsurgical complications leads to the conclusion that care should be taken whenever applying this technique on a routine basis.

**KEY WORDS:** accuracy, complications, dental implants, guided surgery, stereolithography, surgical template

---

## INTRODUCTION

Osseointegration of dental implants has shown to be predictable provided adequate surgical and prosthetic

handling.<sup>1</sup> Thorough presurgical planning is a prerequisite for a successful treatment outcome<sup>2</sup> and includes anatomical as well as prosthetic considerations to precisely position the implants. Conventional periapical and panoramic imaging techniques combined with visual inspection and clinical palpation may be insufficient to obtain the best presurgical planning in complex or compromised cases. Three-dimensional imaging techniques<sup>3</sup> may add an extra dimension to routinely available preoperative radiographs. This can be especially useful as they provide more detailed information regarding bone volume, bone quality or anatomical restrictions.<sup>4</sup> Data obtained by computed tomography (CT), cone beam computed tomography (CBCT) or

---

<sup>\*</sup>Tandkliniek Sint-Lievens-Houtem, Sint-Lievens-Houtem, Belgium; <sup>†</sup>Department of Periodontology and Oral Implantology, Dental School, Faculty of Medicine and Health Sciences, University of Ghent, Ghent, Belgium; <sup>‡</sup>Division of Periodontology, Department of Dental Medicine, Karolinska Institutet, Huddinge, Sweden

Reprint requests: Mr. Jan D'haese, Tandkliniek Sint-Lievens-Houtem, Schoolstraat 2b, 9520 Sint-Lievens-Houtem, Belgium; e-mail: jdhaese@base.be

© 2010 Wiley Periodicals, Inc.

DOI 10.1111/j.1708-8208.2010.00275.x

magnetic resonance imaging can be processed in commercially available implant simulation software and provide a preoperative view of anatomical structures in the jaw bone related to a scanning template representing the future restoration.<sup>5-9</sup> Hereby it becomes possible to virtually plan the ideal implant position taking both anatomical and restorative information into account.<sup>5-9</sup> The virtually planned implant position can afterwards be transferred to the patient and steer the surgical procedure. The used method should be precise and ensure a high level of reproducibility. Several software systems have been developed and are used on a large scale worldwide. Today, there are three practical ways to apply this technique in a clinical setting: guided surgery using drill guides processed by stereolithographic rapid prototyping,<sup>10-14</sup> computer-milled templates,<sup>15-17</sup> or computer navigation systems.<sup>18</sup> Computer-milled templates are fabricated by drilling the final position of the implants in the scanning template itself using a drilling machine. Computer navigation systems allow an intraoperative real-time bur tracking according to the preoperative planned trajectory. It is beyond the purpose of this article to evaluate accuracy in implant placement using computer-milled templates or computer navigation systems.

Guided implant surgery can be especially useful in cases with critical bone volume or anatomy where a unique and ideal implant location is mandatory for enhancing esthetics or in cases where implants are placed with a minimal surgical exposure of bone or even with a flapless approach. Tables 1 and 2 summarize the advantages and disadvantages of this technique. Guided surgery encroaches both anatomical and prosthodontical considerations and probably facilitates the prosthetic reconstruction.

A stereolithographic guided surgery system mainly consists of a stereolithographic surgical guide with implant system-related mounts for fixture installation,

**TABLE 1 Advantages of Flapless Guided Surgery**

Facilitated surgical procedure
Reduced surgical intervention time
Reduced postoperative sequelae
Treatment of medically compromised (anticoagulantia, bisfosfonates, etc.) or anxious patients
Avoiding bone grafting procedures
Facilitated immediate loading protocol

**TABLE 2 Disadvantages of Flapless Guided Surgery**

Lack of visibility and tactile control during surgical procedure
Insufficient mouth opening jeopardizes surgical procedure
Risk of damaging vital anatomical structures

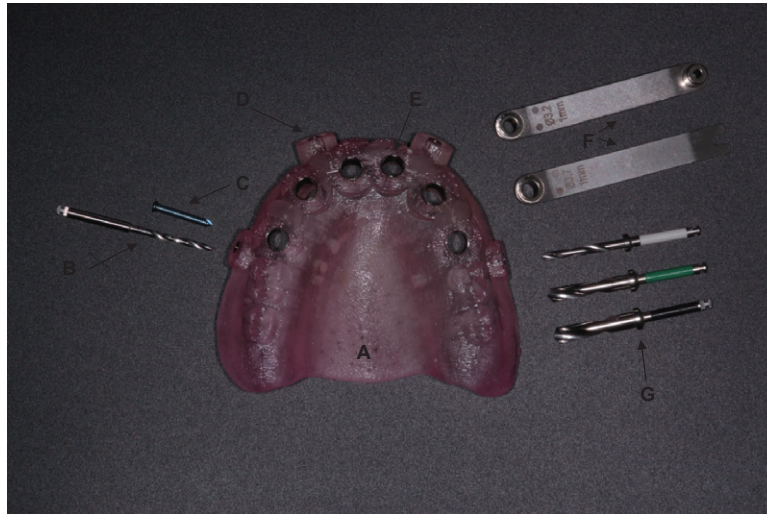
additional guide sleeves for fixation screw installation, drill keys of different heights, and depth-calibrated drills to prepare the osteotomies. A detailed example of one system is presented in Figure 1. Most systems allow the fabrication of a skeletal-, dental-, or mucosal-supported surgical guide. Dental- and mucosal-supported guides can be useful for application of flapless surgery. This in contrast with the use of a bone-supported guidance system where flap surgery remains inevitable. Flapless implant surgery has the main advantage that the postoperative discomfort is drastically reduced as shown in a study of Fortin and coworkers.<sup>19</sup> On the other hand, lack of visibility of anatomical features and critical structures, such as nerves and blood vessels, imposes careful implementation of this technique. Additionally, possible deviations between the preoperative plan and the postoperative implant location require attention because they may lead to important clinical consequences. A study of Van de Velde and coworkers<sup>20</sup> reported frequent perforations when flapless surgery was performed with a freehanded approach. A flapless guided technique can offer implant treatment to patients who would be excluded for conventional implant procedures.

## AIM

The aim of the present paper is to scrutinize the currently available literature regarding accuracy and surgical and prosthodontical complications using stereolithographical surgical guides for implant rehabilitation.

## MATERIALS AND METHODS

A literature search was performed including papers from January 1988 until September 2009. Following keywords were used in the PubMed search engine: “three dimensional imaging,” “image based surgery,” “flapless guided surgery,” “customized drill guides,” “computer-assisted surgery,” “surgical template,” “stereolithography.” Additional references found through reading of selected papers completed the list. Only papers in English were



**Figure 1** Overview of surgical components and instruments used in a stereolithographic guided surgery system (Facilitate™ software system, Astra Tech AB, Mölndal, Sweden): A, Stereolithographic surgical guide. B, Fixation screw drill. C, Fixation screw. D, Guide sleeve for fixation screw installation. E, Guide sleeve for fixture installation. F, Drill keys inserted in the guide sleeves to guide drilling procedure. G, Depth calibrated drills.

selected. The literature search was limited to dental journals. Table 3 shows a list of used keywords and PubMed search terms and the corresponding number of hits. Table 4 lists the additionally searched dental journals. Table 5 gives an overview of all selected articles. Papers reporting on computer-milled templates, computer navigation systems or stereolithographic guides for placement of orthodontic mini implants are beyond the purpose of this article and were excluded from the literature search.

## ACCURACY

To evaluate accuracy using guided surgery, the deviation between the virtual implant planning and the postoperative implant position has to be evaluated. It is very useful in this respect to match a postoperative CT scan

with the preoperative planning. As a consequence, four deviation parameters can be measured as shown in Figure 2. These are global deviation and furthermore angular, depth, and lateral deviation.<sup>20</sup> All parameters, except the angular deviation, are determined for both the coronal and the apical center. The global deviation is defined as the 3D distance between the coronal (or apical) center of the corresponding planned and placed implants. The angular deviation is calculated as the three-dimensional angle between the longitudinal axis of the planned and placed implant. To establish the lateral deviation, a plane perpendicular to the longitudinal axis of the planned implant and through the

**TABLE 3** Used PubMed Search Terms and Corresponding Hits

Keyword	Number of Hits
Three-dimensional imaging	1,507
Image based surgery	225
Flapless guided surgery	23
Customized drill guides	2
Computer-assisted surgery	1,345
Surgical template	214
Stereolithography	52

**TABLE 4** List of Journals Additionally Searched for Article Retrieval

*The International Journal of Oral and Maxillofacial Implants*  
*Journal of Periodontology*  
*The International Journal of Periodontics and Restorative Dentistry*  
*Dentomaxillofacial Radiology*  
*Practical Periodontics and Aesthetic Dentistry*  
*Quintessence International*  
*International Magazine of Oral Implantology*  
*Journal of Oral Implantology*  
*Journal of Clinical Periodontology*  
*Clinical Implant Dentistry and Related Research*  
*Clinical Oral Implant Research*

**TABLE 5 Articles Published Reporting on Accuracy Using Stereolithographic Surgical Guides**

Reference	Study Design	Concept of the Radiological and/or Surgical Guide	Program	Results (Accuracy)
9	Descriptive	A radiographic template containing gutta-percha markers. Surgical template for transfer of the CT-based planning to the patient.	Litorim	Not reported
12	Ex vivo Clinical	A stereolithographic technique generating a jaw bone model and a surgical guide from the CT data.	Litorim	Implant entry: average 0.8 mm (SD 0.3) max: 1.4 mm. Target level an average of 0.9 mm (SD 0.3 mm) max: 1.5 mm. Axis: average: 1.8° (SD 1.0) max 3.8_
24	Ex vivo	A stereolithographic technique generating a jaw bone model and a surgical guide from the CT data.	Litorim	Deviation in angulation: <3° in 4 of 6 cases, max: 3.1° Maximum deviation at the exit point: 2.7 mm
13	In vitro	A comparison between a conventional surgical guide and a customized stereolithographic drill guide (surgiguide), containing cylinders with increasing diameter.	Simplant®	Deviation at the coronal level: max: 1.9 mm, on average 0.9 mm (SD 0.5), at the apical level: max: 2.2 mm, on average 1.0 mm (SD 0.6 mm). Deviation of the angle: max 6.5°, on average 4.5°(SD 2) (data surgiguide).
21	Ex vivo	Three study groups using different software planning systems.	Artma virtual patient™/ RoBoDent®/ Surgiguide®	Artma: Shoulder global: 1.2 ± 0.6 mm Apex depth: 0.8 ± 0.7 mm Axis: 8.1° ± 4.9° RoBoDent®: Shoulder global: 1 ± 0.5 mm Apex depth: 0.6 ± 0.3 mm Axis: 8.1° ± 4.6° Surgiguide®: Shoulder global: 1.5 ± 0.8 mm Apex depth: 0.6 ± 0.4 mm Axis: 7.9° ± 5°
14	Ex vivo	A stereolithographic technique generating a surgical guide from cone beam CT data.	Procera®	Linear deviation apex: 2.0 mm (SD 0.7). Linear deviation hex: 1.1 mm (SD 0.7) angular deviation: 2° (SD 0.8)
36	Clinical	A stereolithographic technique generating a surgical guide from the CT data.	Teeth in-an-hour®	Not reported
37	Clinical	A stereolithographic technique generating a jaw bone model and a surgical guide from the CT data.	Teeth in-an-hour®	Not reported
17	Descriptive	Radiographic template containing Radio-opaque markers. Computer-milled surgical template.	Simplant®	Not reported

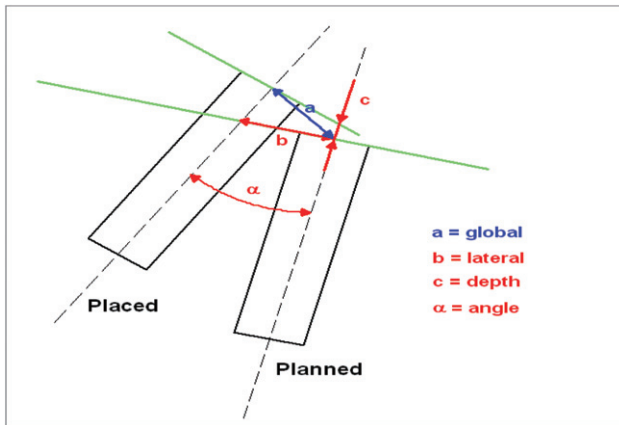
TABLE 5 Continued				
Reference	Study Design	Concept of the Radiological and/or Surgical Guide	Program	Results (Accuracy)
25	Clinical	Customized stereolithographic drill guide (surgiguide). Containing cylinders with increasing diameter to guide the successive drills.	Simplant®	Zygoma: coronal: mean = 2.8 mm, max: 7.4 mm; apical: mean = 4.5 mm, max: 9.7 mm. Angle: 5.1° max: 9.0° Regular: coronal: 1.51 mm, max: 4.7 mm, apical: 3.07 mm, max: 6.4 mm. Angle: 10.46°, max: 21.0°. Pterygoid: coronal: 3.57 mm, max: 7.8 mm. apical: 7.77 mm, 16.1 mm. Angle: 10.18°, 18.0°
11,13	Ex vivo	A comparison between a conventional surgical guide and a customized stereolithographic drill guide (surgiguide), containing cylinders with increasing diameter.	Simplant®	Deviation at the coronal level: max: 1.9 mm, on average 0.9 mm (SD 0.5), at the apical level: max: 2.2 mm, on average 1.0 mm (SD 0.6 mm). Deviation of the angle: max 6.5°, on average 4.5° (SD 2) (data surgiguide).
11,13	Clinical	A radiological template, containing surgical foil. Several stereolithographic guides, each containing cylinders with increasing diameter.	Simplant®	Not reported
38	Clinical	Surgiguide® (for each diameter) Immediate loading.	Simplant®	Not reported
39	Clinical	Scannographic template (Barium conc. teeth, radiolucent base). Surgiguide®. Immediate loading of the implants.	Simplant®	Not reported
10	Clinical	Radiological template containing 10% high-density barium varnish. Surgiguide® containing cylindrical tubes with increasing diameter.	Simplant®	Axis: $7.25 \pm 2.67^\circ$ , max: $12.2^\circ$ . Shoulder: $1.45 \pm 1.42$ mm, max: 4.5 mm. Apex: $2.99 \pm 1.77$ mm, max: 7.1 mm
40	Descriptive	Customized stereolithographic drill guide (Surgiguide®).	Simplant®	Not reported
41	Clinical	A radiographic guide (radiopaque Ivoclar teeth). Stereolithographic drill guide (surgiguide®). Flapless surgery. Immediate loading.	Simplant®	Not reported
42	Descriptive	Customized stereolithographic drill guide (Surgiguide®).	Simplant®	Not reported
43,44	Descriptive	A radiographic guide (barium sulphate/ radiopaque markers at the occlusal surface/ radiopaque Ivoclar teeth). Stereolithographic drill guide (Surgiguide®). A template for each diameter or one template with interchangeable sleeves.	Simplant®	Not reported
43,44	Clinical	A radiographic guide (gutta-percha markers). Customized stereolithographic drill guides (Surgiguide®).	Simplant®	Not reported

**TABLE 5 Continued**

Reference	Study Design	Concept of the Radiological and/or Surgical Guide	Program	Results (Accuracy)
45,46	Descriptive	Scannoguide (barium concentration gradient). Customized stereolithographic drill guide (Surgiguide). Flapless surgery. Immediate loading.	Simplant®	Not reported
47	Clinical	A radiological template, containing a radiopaque pin, indicating the desired prosthetic location. A surgical guide, indicating the implant position as planned in the software program.	ImplantMaster®	Not reported
48	Clinical	A comparison between dynamic and static computer-assisted guidance methods. Three different static methods are described.	Simplant® Med3D coDiagnostix®/ gonyX	Not reported
22	Clinical	A radiographic guide containing barium sulfate. A surgical guide indicating the implant position as planned in the software.	Stent Cad®	Axis: $4.1^\circ \pm 2.3^\circ$ Shoulder linear: $1.11 \pm 0.7$ mm Apex linear: $1.41 \pm 0.9$ mm
23	Clinical Multicenter	A radiopaque diagnostic appliance for CT scanning. A stereolithographic drill guide for each drill diameter.	Simplant®	Lateral deviation coronal: $1.4 \pm 1.3$ mm Lateral deviation apical: $1.6 \pm 1.2$ mm Depth deviation apical: $1.0 \pm 1.0$ mm Angular deviation: $7.9^\circ \pm 4.7^\circ$
49	Clinical	Customized stereolithographic drill guide (Surgiguide®). Containing cylinders with increasing diameter to guide the successive drills.	Simplant®	Not reported
21	Ex vivo	Three study groups using different software planning systems.	Artma virtual patient™/ RoBoDent®/ Surgiguide®	Artma: Shoulder global: $1.2 \pm 0.6$ mm; Apex depth: $0.8 \pm 0.7$ mm; Axis: $8.1^\circ \pm 4.9^\circ$ RoBoDent®: Shoulder global: $1 \pm 0.5$ mm; Apex depth: $0.6 \pm 0.3$ mm; Axis: $8.1^\circ \pm 4.6^\circ$ Surgiguide®: Shoulder global: $1.5 \pm 0.8$ mm; Apex depth: $0.6 \pm 0.4$ mm; Axis: $7.9^\circ \pm 5^\circ$
50	Case report	A radiographic template duplicated from the diagnostic wax-up. Multiple surgiguides using tube diameters of increasing size.	Simplant®	Not reported
51	Case report	A stereolithographic technique generating a jaw bone model and a surgical guide from the CT data.	Procera®	Not reported
52	Clinical	A radiographic template duplicated from the diagnostic wax-up. Multiple surgiguides using tube diameters of increasing size.	Simplant®	Mesiodistal angular deviation: $0.2^\circ \pm 5.1^\circ$ Buccolingual angular deviation: $0.5^\circ \pm 4.5^\circ$ Global coronal deviation: $0.2 \pm 0.35$ mm

SD = standard deviation.





**Figure 2** Three-dimensional evaluation of the virtual planned and the in vivo placed implants.

coronal (or apical) center is defined and as reference plane. The lateral deviation is defined as the distance between the coronal (or apical) center of the planned implant and the intersection point of the longitudinal axis of the placed implant with the reference plane. The depth deviation is the distance between the coronal (or apical) center of the planned implant and the intersection point of the longitudinal axis of the planned implant with a plane parallel to the reference plane and through the coronal (or apical) centre of the placed implant.

### In Vitro Studies Reporting on Accuracy

A preclinical study<sup>13</sup> compared the accuracy of conventional surgical guides with that of a stereolithographic surgical guide (Table 6). CT scanning of five identical epoxy edentulous mandibles was performed using a CBCT scanner. Five surgeons performed osteotomies, each on one model. On the right side a conventional surgical guide was used (control) and on the left side a stereolithographic guide was used (test). Postoperative, each jaw was rescanned and a registration method was applied to match it to the initial planning. On the control side the average deviation at the entrance point

was 1.5 mm compared with 2.1 mm at the apex of the implants. When using the stereolithographic guide these deviations were significantly reduced to 0.9 and 1.0 mm, respectively. Additionally, variations between and within the surgeons were reduced compared with conventional surgery. Hence, it was concluded that a more accurate transfer was obtained with guided implant surgery.

### Ex Vivo Studies Reporting on Accuracy

A double scan procedure was introduced using a radiographic template (acrylic denture with small gutta percha markers) to visualize an acrylic resin scanning template. In a second stage, the patient was scanned with the same template in the mouth. The two data sets were fused on the basis of the radiopaque markers by a special developed software package.<sup>9</sup> A stereolithographic technique was used to generate a surgical guide from the CT data. Ex vivo studies describing the outcome of this technique are summarized in Table 7. This double scan procedure was first tested on two cadavers and later in eight consecutively treated patients.<sup>12</sup> A bone-supported stereolithographic guide was placed after raising a mucoperiosteal flap. The trial in the two cadaver specimens indicated that the drilling template achieved an appropriate fit onto the underlying bone. The drills and implants were well guided because of the intimate fit with the internal sleeves in the guide. Postoperatively, a second CT scan was taken and the implant locations were compared based on an image volume registration technique. At the shoulder of the implant, the deviation was 0.8 mm (standard deviation [SD] 0.3) and at the apex the deviation was on average 0.9 mm (SD 0.3). The differences between placed and planned implants were most prominent in the longitudinal direction of the implants, supporting the fact that shorter implants could be placed more accurately. In the eight consecutive patients, all implants were successfully fitted onto the abutments to be immediately loaded with a prefabricated definitive fixed prosthesis. However, a slight space,

**TABLE 6** In Vitro Studies Reporting on Accuracy Using Stereolithographic Surgical Guides for Regular Implants Based on Coronal, Apical, and Maximal Deviations Expressed in mm and Degree of Angular Deviation

Reference	Support	Program	Coronal Deviation (mm)	Apical Deviation (mm)	Maximal Deviation (mm) (Coronal/Apical)	Angular Deviation (Degree)	Maximal Angular Deviation (Degree)
13	Bone	Simplant	0.9	1.0	1.2/1.6	4.5°	5.4°

**TABLE 7 Ex Vivo Studies Reporting on Accuracy Using Stereolithographic Surgical Guides for Regular Implants Based on Coronal, Apical, and Maximal Deviations in mm and Degree of Angular Deviation**

Reference	Support	Program	Coronal Deviation (mm)	Apical Deviation (mm)	Maximal Deviation (mm) (Coronal/Apical)	Angular Deviation (Degree)	Maximal Angular Deviation (Degree)
12	Bone	Litorim®	0.8	0.9	1.4/1.5	1.8°	3.8°
21	Bone	Artma virtual patient™/ RoBoDent®/Surgiguide®	1.5*	0.6†	NR	7.9°	NR
14	Dental/mucosal	Nobelguide®	1.1	1.2	2.3/2.4	2°	4°

\*Specified as lateral.

†Specified as depth.

NR = not reported.

indicative of a bad fit, appeared on the postoperative orthopantomogram between the implants and the abutments in 5 out of 61 implants. The authors related this to the difficulty in keeping visual control during screwing of the abutment onto the implants. Unfortunately, no measurements on accuracy are presented in the article for these case series.

Another ex vivo study reported a total of 120 implants placed in 20 human cadaver mandibles.<sup>21</sup> Implant placement was performed using either optical tracking or stereolithographic bone-supported splints. Osteotomies were performed using three splints with increasing diameter of the drill sleeves. After implant socket preparation, the splints were removed and the implants were placed manually within the prepared implant beds. Deviations between planned and achieved positions were measured for each implant. In the stereolithographic group, a mean coronal deviation of  $1.5 \pm 0.8$  mm, a mean depth deviation of  $0.6 \pm 0.4$  mm and a mean axis deviation of  $7.9^\circ \pm 5^\circ$  were reported. No statistically significant differences were observed when comparing the optical tracking subgroup versus the stereolithographic subgroup. In another study, the precision of a computer-based three-dimensional planning, using reformatted CBCT images, for implantation in partially edentulous jaws was evaluated.<sup>14</sup> Four cadaver jaws (one maxilla and three mandibles) were selected and virtual implant simulation was performed based on three-dimensional CBCT images (3D Accuitomo FPD, J.Morita, Kyoto, Japan). In total, 12 self-tapping implants were installed, using a combination of dental- and mucosal-supported stereolithographic guides. Post-operatively, a second CBCT scan was taken to check the positioning of the implants. Deviations ranged between

0.3 and 2.3 mm at the 10 of the implants (mean 1.1 mm), and 0.3 and 2.4 mm (mean 1.2 mm) at the apex. Mean angular deviation was 1.8°. Implants with neighbouring teeth supporting the guide often showed smaller deviations than distal implants placed using a free-ending template. We could conclude that the larger the extension of the dento-mucosal-supported guide, the larger the risk of having a bending effect of the template in the posterior region. When analyzing all data, mean coronal deviations ranged between 0.8 and 1.5 mm (mean 1.13 mm); mean apical deviations ranged between 0.6 mm and 1.2 mm (mean 0.9 mm) and mean angular deviations ranged between 1.8° and 7.9° (mean 3.9°).

#### Clinical Studies Reporting on Accuracy Using Standard Oral Implants

In a prospective clinical study,<sup>10</sup> four healthy, nonsmoking patients were enrolled requiring in total 21 implants (Table 8). A diagnostic cast was duplicated and the edentulous areas were coated with a mixture composed of 10% high-density barium in 90% varnish to serve as a scanning template. A CT scan was taken without inter-arch contact and the resulting DICOM images were converted. Three bone-supported stereolithographic surgical guides with increasing drill sleeve diameter were fabricated for each surgical area. Fixtures were inserted without the surgical guide. No stabilization screws were used. After surgery, a new CT scan was taken and both scans were aligned observing superposition of anatomic markers and the edentulous areas of the template. Mean deviations of 1.45 mm (SD 1.42) at the implant shoulder and 2.99 mm (SD 1.77) at the apex were reported. The match between the planned and achieved implant



**TABLE 8 In Vivo Studies Reporting on Accuracy Using Stereolithographic Surgical Guides for Regular Implants Based on Coronal, Apical, and Maximal Deviations Expressed in mm and Degree of Angular Deviation**

Reference	Support	Program	Coronal Deviation (mm)	Apical Deviation (mm)	Maximal Deviation (mm) (coronal/apical)	Angular Deviation (degree)	Maximal Angular Deviation (degree)
10	Bone/teeth	Simplant®	1.45	2.99	NR	7.25°	NR
22	Bone/teeth/mucosa	Stent Cad®	1.06 (mucosa)	1.60 (mucosa)	NR	4.51° (mucosa)	NR
			0.87 (tooth)	0.95 (tooth)		2.94° (tooth)	
			1.28 (bone)	1.57 (bone)		1.57° (bone)	
23	Teeth/mucosa	Simplant®	1.4*	1.6*	6.5*/ 6.9*	7.9°	24.9°
52	Bone	Simplant®	0.2	NR	NR	0.17‡	12.2‡
						0.46§	7.67§

\*Specified as lateral.

†Specified as depth.

‡Specified as mesiodistal.

§Specified as buccolingual.

NR = not reported.

axis was on average 7.25° (SD 2.67). The deviations were caused by the ill fitting of some of the templates on the teeth or absence of a stable fit on the bone. A slighter difference was seen when a bone-supported mandibular guide extended to both the right and left side of the mandible. This points out the importance of having a proper fit of the template on a surface that is as large as possible. Another in vivo study<sup>22</sup> evaluated 110 implants whereby 30 implants were placed using tooth-supported guides, 50 using bone-supported guides, and 30 using mucosal-supported guides. A mean angular deviation of 4.51° ± 2.7° in the mucosa group, 2.91° ± 1.3° in the tooth-supported group and 4.63° ± 2.6° in the bone-supported group was reported. The mean coronal/apical deviations were 1.06 ± 0.6 mm/1.60 ± 1.0 mm for the mucosal-supported guides, 0.87 ± 0.4 mm/0.95 ± 0.6 mm for the tooth-supported guides, and 1.28 ± 0.9 mm/1.57 ± 0.9 mm for the bone-supported guides. A statistically significant difference was found between the treatment groups for angular and global apical deviation of the placed implants. Tooth-supported guides showed significant smaller deviations compared with mucosal- and bone-supported guides. In a retrospective multicenter study,<sup>23</sup> 18 partial and 10 full edentulous arches were operated. The surgical guides were classified according to the type of supporting anatomical structure being bone, mucosa or teeth. Three different surgical guides, with increasing sleeve diameter, were used in each case. Implant insertion was again

performed free-handed. Eighty-nine out of 104 implants were analyzed postoperatively. Mean lateral deviation at apical point was 1.6 mm, mean depth deviation 1.1 mm and mean angular deviation 1.9°. For the apical deviation paired comparisons demonstrated better accuracy of mucosal-supported guides. Smaller apical deviations were found in the maxilla compared with the mandible and in completely edentulous compared with partially edentulous patients. No significant differences were observed between the two study centers. In three sites the implant placement was impossible because of loss of the entire buccal plate. Additionally, the chosen implant length at surgery differed from the initial planning in 11 sites because of an insufficient mouth opening or fear of the operator to injure vital anatomic structures. One template cracked during surgery and the metal tubes in one guide plate were detached while performing implant bed preparation. Our analysis showed that coronal deviations ranged between 0.2 and 1.45 mm (mean 1.04 mm), apical deviations ranged between 0.95 and 2.99 mm (mean 1.64 mm) and mean angular deviation ranged between 0.17° and 7.9° (mean 3.54).

### Accuracy Using Zygoma and Pterygoid Implants

Accuracy using zygoma and pterygoid implants was reported in two papers summarized in Table 9. The length of these implants is three to four times that of a

**TABLE 9 In Vivo Studies Reporting on Accuracy Using Stereolithographic Surgical Guides for Zygomatic and/or Pterygoid Implants Based on Coronal, Apical, and Maximal Deviations Expressed in mm and Degree of Angular Deviation**

Reference	Support	Program	Coronal Deviation (mm)	Apical Deviation (mm)	Maximal Deviation (mm) (Coronal/Apical)	Angular Deviation (Degree)	Maximal Angular Deviation (Degree)
24	Bone	Litorim/surgiguide	2.32	2.9	6.0/7.9	2.74°	6.93°
25	Bone	Surgiguide	2.8	4.5	7.4/9.7	5.1°	9.0°

standard oral implant. This means that even slight angular deviations may lead to important deviations at the extremity. In one *ex vivo* study,<sup>24</sup> six zygoma fixtures with a length of 45 mm were planned in three cadaver heads using a custom made bone-supported drilling with intimate fitting to the underlying jawbone. In four of the six implants, the angle between the placed and the planned implants was less than 3°. The largest deviation noted was 6.9° resulting in a measurable deviation of 6.74 mm in craniocaudal direction at the apex of the implant. The author explained this by the fact that a metal cylinder came loose during the surgery.

A clinical study reported on 29 cases with zygoma, pterygoid and standard oral implants<sup>25</sup> using bone-supported guides. The osteotomies were performed using only two drills with corresponding guide sleeves but the fixtures were manually installed without the guide. After implant surgery, a postoperative CT scan was taken of 12 randomly selected patients to be matched with the preoperative planning<sup>26</sup> and the deviations were calculated.<sup>27</sup> For the zygoma implants, the maximum deviation was 7.4 mm coronally (mean 2.8 mm), 9.7 mm apically (mean 4.5 mm), and 9.0° for the angular deviation (mean 5.1°). For the standard implants installed the maximum deviation was 4.7 mm (mean 1.51 mm) coronally and 6.4 mm (mean 3.07 mm) apically. The pterygoid implants deviated on average 3.57 mm (range 0.2–7.8) at the entry point and 7.77 mm (range 1.1–16.1) at the exit point. The average axis deviation was 10.18° (range 1.7°–18.0°). Probably because of the substantial deviations from the planning disappointing cumulative implant survivals were reported, two zygoma implants (7% failures) and four pterygoid implants (29% failures) were lost because of this misplacement. Six standard implants were lost (8% failures) because no initial implant stability was achieved at the time of surgery. The author explained that all patients suffered from severe atrophy of the max-

illary bone and had a low bone quality according to the Misch classification.<sup>28</sup> Furthermore, manual fixture installation may have imposed an extra risk for additional misplacement.

Summarizing the scrutinized papers regarding zygoma and pterygoid implants, one can conclude that the overall coronal, apical, or angular deviation is, respectively, 2.56 mm, 3.7 mm and 3.92°.

In conclusion, it can be stated that only 10 publications compared the preoperative implant planning with the postoperative implant locations. Hence very few papers evaluated accuracy of computer guided stereolithographic surgery in a scientifically objective way. All data published indicate that a substantial deviation is found between virtually planned and *in vivo* placed implants. Enlarging a stiff surface for guide positioning improves the accuracy, although bone-supported guides are less accurate than teeth-supported ones. Although flapless surgery is quite often used in daily practice, very few papers on accuracy are available when using stereolithographic mucosal-supported surgical guides for full jaw rehabilitation in maxilla or mandible. Additionally, the study designs reporting on different supporting surfaces (dental and mucosal), different implant systems or designs (standard oral implants and zygoma/pterygoid implants) and the rather limited number of implants included in the papers lead to the conclusion that the evidence on accuracy is lacking.

## COMPLICATIONS

Although several reports have shown that guided implant surgery based on computer-assisted virtual treatment planning can offer an acceptable outcome, surgical and technical complications occurring during the procedure have been scarcely reported (Table 10). Up to now the accuracy of each different step in the procedure, which can affect the final outcome, is not yet fully understood. The following paragraph describes

**TABLE 10 Implant Survival Rate (%), Prosthetic Survival Rate (%), and Complications (%) Encountered during the Treatment of Stereolithographic Flapless Guided Surgery and Immediate Loading with a Prefabricated Prosthesis**

Reference	Implant Survival Rate	Prosthetic Survival Rate	Complications
29	100% (maxilla)	100% (maxilla)	Surgical and technical
34	Nonsmokers: 98.9% Smokers: 81.2%	NR	NR
36	97.60%	100%	1.2% misfit
32	92% (maxilla)	90% (maxilla)	42% surgical and technical
32	83% (mandible)	70% (mandible)	42% surgical and technical
31	89.90%	79.60%	Surgical and technical

NR = not reported.

currently available information regarding complications encountered during the treatment of computer-guided flapless surgery in conjunction with immediate loading with a prefabricated prosthesis. In one prospective multicenter study,<sup>29</sup> 27 patients with totally edentulous maxillae were treated and followed for 1 year. According to the protocol, implants were installed by the aid of a CT scan-derived customized surgical template for flapless surgery and a prefabricated final prosthesis was delivered immediately after surgery. Several postoperative complications observed from the day of surgery up to 1 year were encountered. They were classified as moderate postoperative pain (4/23 cases), marginal fistula (1/23 cases), occlusal material fracture of the prosthesis (2/23 cases), loosening of retaining screws (1/23 cases), slight discrepancies between the abutments and implants (1/23 cases), and midline deviation of the prosthetic rehabilitations (1/23 cases). At the 1-year examination, signs of inflammation or hyperplasia of the gingiva or alveolar mucosa were observed in 4/23 patients. It was further mentioned that one surgeon used a shorter implant because he felt that he would penetrate the nasal or sinus cavity during the drilling. In spite of these inaccuracies, all implants and all suprastructures survived up to 1 year. However, scientific information regarding bone loss in order to describe implant success was lacking. Another clinical trial presented some complications when using computer-guided flapless surgery with immediate loading of prefabricated all-acrylic prosthesis supported by four implants.<sup>30</sup> Twenty-three patients with either edentulous maxilla or mandible treated with a total number of 92 implants were followed between 6 and 21 months. The complications were categorized into either mechanical or soft tissue problems. Most fre-

quently encountered mechanical complications were fractures of the complete acrylic denture (8/23 cases) and these were associated with bruxism or technical features. Abutment screw loosening occurred in two patients. Signs of peri-implant pathology with local bone defects, pocket formation, bleeding on probing, and mucosa inflammation around implants were observed in two patients. These problems were apparently solved or treated either by a strict hygiene maintenance program or a surgical management to prevent further progress. One astonishing result is the reported mean marginal bone loss of 1.9 mm and bone loss of more than 2 mm in 28% of the fixtures at 1 year. These numbers indicate a rather high bone loss when compared with conventional surgical techniques and not all implants were included in the radiographic evaluation. Another paper reported surgical and prosthetic complications during the treatment process, from planning to postoperative follow-up.<sup>31</sup> Seventy-eight implants in 13 patients with either completely/partially or maxillary/mandibular jaws were included. A final or provisional prosthesis was connected to the implants immediately after surgery. The complications were classified as "early complications" and "late complications." As for early complications none were observed with the planning procedure. During the surgery and prosthesis connection, two prostheses did not seat completely because of bony interference and one implant failed immediately because of incomplete placement to depth. Several additional complications occurred during the 1-year follow-up. These were sometimes easy to solve, but others required expensive aftercare and had an impact on patient centered outcome. Prosthesis loosening (1/13 cases), speech problems (1/13 cases), and bilateral cheek

biting (1/13 cases) were also reported as early prosthetic complications. Persistent pain (1/13 cases), a residual buccal soft tissue defect around one implant (1/78 implants), and seven implant failures (7/78 implants) were registered as late surgical complications. The overall failure rate was 9% and more frequently seen in the maxilla than in the mandible. Late prosthetic complications such as heavy occlusal wear (2/13 cases), loosening of screws (2/13 cases), fracture of prosthesis (3/13 cases), aesthetic dissatisfaction (1/13 cases), and pressure sensitivity (1/13 cases) were more often found in the carbon fiber frameworks with acrylic resin than in porcelain fused metal bridges or milled titanium frames with acrylic denture teeth. Nearly simultaneously with the previous paper treatment outcome of immediately loaded implants installed in edentulous jaws following computer-assisted virtual treatment planning and flapless surgery was reported.<sup>32</sup> This study included 29 patients (31 jaws) with edentulous maxilla, mandible, or both. In this report surgical and technical complications occurred in 13 of the 31 cases (42%). Three surgical templates fractured either before surgery or at the removal of the template after implant installation. Misfit of the suprastructure appeared in five cases, resulting in the disconnection of the suprastructure in two cases where fixtures were left for unloaded healing. Extensive occlusal adjustment was made in three cases. In these cases correction was made either by re-alignment of a denture in the opposing jaw or remaking of the implant-supported suprastructure. Radiographic bone defects after drilling developed in three cases. These appeared in two cases after anchor-pin drilling in the maxilla and in another case in a severely resorbed mandible. Some of these complications may have affected the implant survival rate of 92% in the maxilla and 84% in the mandible. The outcome of this study showed disappointing lower survival rates in the edentulous mandible comparing to the maxilla. It was described that dense mandibular jaw bone gave tension to a more fragile drill guide, which may have caused the surgical guide fracture. Another possible explanation is that directly saline irrigation on the bone surface is unmanageable because of the interruption by the acrylic surgical template. This might be critical, especially in the dense mandible and cause overheating of the bone. A 1-year prospective multicenter study in eight clinics in Scandinavia<sup>33</sup> included a total of 312 implants in 52 patients with edentulous maxillae. Surgical and prosthetic prob-

lems, soft tissue complications, and, in addition, marginal bone resorption were reported after 1 year. The surgical-related problems included misfit of the surgical silicone index (3/52 cases) or the surgical guide (2/52 cases) and often difficulties in the proper placement of implants and abutments. Correct fitting of the prosthesis was difficult in 10/52 cases and major occlusal correction was required in three patients. In one case the prosthesis was remade using standard abutments to achieve better oral hygiene. At 1-year examination inflammation was recorded in 23% and local pain was noted in 3% of all sites. Mean marginal bone loss after 1 year was 1.3 mm (SD 1.28) and bone loss over 2 mm was seen in 19% of the implants. This bone loss is more extended compared with conventional flap surgery. In another study,<sup>34</sup> 30 patients were operated, 13 smokers and 17 nonsmokers. Out of 212 implants placed, nine implants failed (4.9%). Eight of these failures occurred in three smokers. A cumulative survival rate of 81.2% after 5 years in heavy smokers compared with 98.9% for nonsmokers was reported and marginal bone loss was 2.6 mm (SD 1.6 mm) in smokers and 1.2 mm (SD 0.8 mm) in non smokers. Hence, smoking was shown to be a possible risk factor affecting implant loss and marginal bone loss when combining flapless surgery with immediate loading. Misfit of an immediately loaded prefabricated definitive fixed complete denture on four implants was described in a case report study.<sup>35</sup> Misfit on one of the fixtures caused a peri-implant infection with substantial bone loss after 5 months. This report, again, pointed to the difficulty of achieving passive fit of a prefabricated metal framework on the inserted implants. Absence of passive fit may further lead to mechanical (screw loosening) and biological (marginal bone loss) complications.

Based on the literature review, complications can be related to the technical procedure or depending on the used hardware. Errors in positioning of the surgical template and overheating during osteotomy is categorized as procedure-related, whereas the accuracy or stiffness of the surgical template and the suprastructure is product-related. Deviation between the planning and the actual implant position might occur at any stage in the treatment: during CT scanning, during transfer of the planning data, during the manufacturing of the surgical template, during positioning the surgical guide, and while installing implants. The only way to solve these complicated problems in order to improve the treatment

is to collect and investigate the complications that occurred in the real clinical situations. Today the development of implant dentistry has shifted towards a more rapid and simplified use, although scientific evidence and substantial long-term studies are lacking. Although acceptable results of guided surgery have been shown in some articles, and despite the widespread introduction in clinical practice, the overall available evidence is scarce especially in mandibular and partial cases. Hence, guided surgery should still be considered as being in the development stage. Further evaluation and monitoring of implant survival, bone loss and clinical complications is required to refine the procedure and the systems. Based on the lower short-term survival rates, surgical and prosthetic complications and keeping in mind that prosthetic complications are normally only expected to occur in a longer follow-up period, it seems reasonable to advise clinicians and patients that this treatment protocol may lead to more overall long-term complications.

## OVERALL CONCLUSION

Guided implant surgery is far from accurate when using computer designed stereolithographic surgical guides. Most authors report deviations between the postoperative position and the preoperative plan. Deviations at the shoulder of the implants hamper the correct fit of a prefabricated construction, and require adaptation of fit or occlusion. Deviations at the apex of the implants can be expected. Hence, a safety zone of at least 2 mm is necessary to avoid critical anatomical structures. The total accuracy is the sum of all errors encountered during the entire process of template production and the clinical application. It has to be considered that most of the data published report on different types of guides (mucosal, dental, bone) and that lower deviations could be expected using a stiff supporting surface. Another important factor is whether the implant installation is done manually or guided. Guided implant placement has a tendency to show smaller deviations. When implant installation is done manually, the implant always tends to follow the trajectory with the least resistance. Especially in patients with a rather soft bone type this could lead to substantial deviations. Complications are frequently reported when combining computer guided flapless surgery with an immediate loaded prefabricated prosthesis. Surgical and prosthetic complications are in most instances caused by the misfit

between the installed implants and the prefabricated prosthesis.

## REFERENCES

1. Albrektsson T, Dahl E, Enbom L, et al. Osseointegrated oral implants. A Swedish multicenter study of 8139 consecutively inserted Nobelpharma implants. *J Periodontol* 1988; 59:287–296.
2. Jacobs R, Adriansens A, Naert I, Quirynen M, Hermans R, van Steenberghe D. Predictability of reformatted computed tomography for preoperative planning of endosseous implants. *Dentomaxillofac Radiol* 1999; 28:37–41.
3. Rothman SL, Chafetz N, Rhodes ML, Schwarz MS, Schwartz MS. CT in the preoperative assessment of the mandible and maxilla for endosseous implant surgery. Work in progress. *Radiology* 1988; 168:171–175.
4. Jacobs R, Adriansens A, Verstreken K, Suetens P, van Steenberghe D. Predictability of a three-dimensional planning system for oral implant surgery. *Dentomaxillofac Radiol* 1999; 28:105–111.
5. Israelson H, Plemons JM, Watkins P, Sory C. Barium-coated surgical stents and computer-assisted tomography in the preoperative assessment of dental implant patients. *Int J Periodontics Restorative Dent* 1992; 12:52–61.
6. Basten CH. The use of radiopaque templates for predictable implant placement. *Quintessence Int* 1995; 26:609–612.
7. Mizrahi B, Thunthy KH, Finger I. Radiographic/surgical template incorporating metal telescopic tubes for accurate implant placement. *Pract Periodontics Aesthet Dent* 1998; 10:757–765.
8. Sarment DP, Misch CE. Scannographic templates for novel pre-implant planning methods. *Int Mag Oral Implantol* 2002; 3:16–22.
9. Verstreken K, Van Cleynenbreugel J, Martens K, Marchal G, van Steenberghe D, Suetens P. An image-guided planning system for endosseous oral implants. *IEEE Trans Med Imaging* 1998; 17:842–852.
10. Di Giacomo GA, Cury PR, de Araujo NS, Sendyk WR, Sendyk CL. Clinical application of stereolithographic surgical guides for implant placement: preliminary results. *J Periodontol* 2005; 76:503–507.
11. Sarment DP, Al-Shammari K, Kazor CE. Stereolithographic surgical templates for placement of dental implants in complex cases. *Int J Periodontics Restorative Dent* 2003; 23:287–295.
12. van Steenberghe D, Naert I, Andersson M, Brajnovic I, Van Cleynenbreugel J, Suetens P. A custom template and definitive prosthesis allowing immediate implant loading in the maxilla: a clinical report. *Int J Oral Maxillofac Implants* 2002; 17:663–670.
13. Sarment DP, Sukovic P, Clinthorne N. Accuracy of implant placement with a stereolithographic surgical guide. *Int J Oral Maxillofac Implants* 2003; 18:571–577.



14. Van Assche N, van Steenberghe D, Guerrero ME, et al. Accuracy of implant placement based on pre-surgical planning of three-dimensional cone beam images: a pilot study. *J Clin Periodontol* 2007; 34:816–821.
15. Fortin T, Champlébourg G, Lormée J, Coudert JL. Precise dental implant placement in bone using surgical guides in conjunction with medical imaging techniques. *J Oral Implantol* 2000; 26:300–303.
16. Fortin T, Champlébourg G, Bianchi S, Buatois H, Coudert JL. Precision of transfer of preoperative planning for oral implants based on cone-beam CT-scan images through a robotic drilling machine. *Clin Oral Implants Res* 2002; 13:651–656.
17. Klein M, Abrams M. Computer-guided surgery utilizing a computer-milled surgical template. *Pract Proced Aesthet Dent* 2001; 13:165–169.
18. Widmann G, Widmann R, Widmann E, Jaschke W, Bale R. Use of a surgical navigation system for CT-guided template production. *Int J Oral Maxillofac Implants* 2007; 22:72–78.
19. Fortin T, Bosson JL, Isidori M, Blanchet E. Effect of flapless surgery on pain experienced in implant placement using an image-guided system. *Int J Oral Maxillofac Implants* 2006; 21:298–304.
20. Van de Velde T, Glor F, De Bruyn H. A model study on flapless implant placement by clinicians with a different experience level in implant surgery. *Clin Oral Implants Res* 2008; 19:66–72.
21. Ruppin J, Popovic A, Strauss M, Spüntrup E, Steiner A, Stoll C. Evaluation of the accuracy of three different computer-aided surgery systems in dental implantology: optical tracking vs. stereolithographic splint systems. *Clin Oral Implants Res* 2008; 19:709–716. Epub 2008 May 19.
22. Ozan O, Turkyilmaz I, Ersoy AE, McGlumphy EA, Rosenstiel SF. Clinical accuracy of 3 different types of computed tomography-derived stereolithographic surgical guides in implant placement. *J Oral Maxillofac Surg* 2009; 67:394–401.
23. Valente F, Schiroli G, Sbrenna A. Accuracy of computer-aided oral implant surgery: a clinical and radiographic study. *Int J Oral Maxillofac Implants* 2009; 24:234–244.
24. van Steenberghe D, Malevez C, Van Cleynenbreugel J, et al. Accuracy of drilling guides for transfer from three-dimensional CT-based planning to placement of zygoma implants in human cadavers. *Clin Oral Implants Res* 2003; 14:131–136.
25. Vrielinck L, Politis C, Schepers S, Pauwels M, Naert I. Image-based planning and clinical validation of zygoma and pterygoid implant placement in patients with severe bone atrophy using customized drill guides. Preliminary results from a prospective clinical follow-up study. *Int J Oral Maxillofac Surg* 2003; 32:7–14.
26. Maes F, Collignon A, Vandermeulen D, Marchal G, Suetens P. Multimodality image registration by maximization of mutual information. *IEEE Trans Med Imaging* 1997; 16:187–198.
27. Martens K, Verstreken J, Van Cleynenbreughel J, et al. Image-based planning and validation of C1–C2 transarticular screw fixation using personalized drill guides. In: Taylor C, Colchester A, ed. *Proceedings 2nd International Conference on Medical Image Computing and Computerassisted Intervention – MICCAI'99, Lecture Notes in Computer Science*. Cambridge: Springer, 1999:860–867.
28. Misch CE. Bone classification, training keys to implant success. *Dent Today* 1989; 8:39–44.
29. van Steenberghe D, Glauser R, Blombäck U, et al. A computed tomographic scan-derived customized surgical template and fixed prosthesis for flapless surgery and immediate loading of implants in fully edentulous maxillae: a prospective multicenter study. *Clin Implant Dent Relat Res* 2005; 7 (Suppl 1):111–120.
30. Malo P, Nobre M, Lopes A. The use of computer-guided flapless implant surgery and four implants placed in immediate function to support a fixed denture: preliminary results after a mean follow-up period of thirteen months. *J Prosthet Dent* 2007; 97:26–34.
31. Yong LT, Moy PK. Complications of Computer-Aided-Design/Computer-Aided-Machining-Guided (Nobel-Guide™) surgical implant placement: an evaluation of early clinical results. *Clin Implant Dent Relat Res* 2008; 10:123–127.
32. Komiya A, Klinge B, Hultin M. Treatment outcome of immediately loaded implants installed in edentulous jaws following computer-assisted virtual treatment planning and flapless surgery. *Clin Oral Implants Res* 2008; 19:677–685.
33. Johansson B, Friberg B, Nilson H. Digitally planned, immediately loaded dental implants with prefabricated prosthesis in the reconstruction of edentulous maxillae: a 1-year prospective, multicenter study. *Clin Implant Dent Relat Res* 2009; 11:194–200.
34. Sanna AM, Molly L, van Steenberghe D. Immediately loaded CAD-CAM manufactured fixed complete dentures using flapless implant placement procedures: a cohort study of consecutive patients. *J Prosthet Dent* 2007; 97:331–339.
35. Oyama K, Kan JY, Kleinman AS, Runcharassaeng K, Lozada JL, Goodacre CJ. Misfit of implant fixed complete denture following computer-guided surgery. *Int J Oral Maxillofac Implants* 2009; 24:124–130.
36. Balshi SF, Wolfinger GJ, Balshi TJ. Guided implant placement and immediate prosthesis delivery using traditional Brånemark System abutments: a pilot study of 23 patients. *Implant Dent* 2008; 17:128–135.
37. Kupeyan HK, Shaffner M, Armstrong J. Definitive CAD/CAM-guided prosthesis for immediate loading of bone-grafted maxilla: a case report. *Clin Implant Dent Relat Res* 2006; 8:161–167.

38. Ganz SD. Use of stereolithographic models as diagnostic and restorative aids for predictable immediate loading of implants. *Pract Proced Aesthet Dent* 2003; 15:763–771.
39. Tardieu PB, Vrielinck L, Escolano E. Computer-assisted implant placement. A case report: treatment of the mandible. *Int J Oral Maxillofac Implants* 2003; 18:599–604.
40. Ganz SD. Presurgical planning with CT-derived fabrication of surgical guides. *J Oral Maxillofac Surg* 2005; 63:59–71.
41. Sudbrink SD. Computer-guided implant placement with immediate provisionalization: a case report. *J Oral Maxillofac Surg* 2005; 63:771–774.
42. Ganz SD. Techniques for the use of CT imaging for the fabrication of surgical guides. *Atlas Oral Maxillofac Surg Clin North Am* 2006; 14:75–97.
43. Lal K, White GS, Morea DN, Wright RF. Use of stereolithographic templates for surgical and prosthodontic implant planning and placement. Part I. The concept. *J Prosthodont* 2006; 15:51–58.
44. Lal K, White GS, Morea DN, Wright RF. Use of stereolithographic templates for surgical and prosthodontic implant planning and placement. Part II. A clinical report. *J Prosthodont* 2006; 15:117–122.
45. Rosenfeld AL, Mandelaris GA, Tardieu PB. Prosthetically directed implant placement using computer software to ensure precise placement and predictable prosthetic outcomes. Part 1: diagnostics, imaging, and collaborative accountability. *Int J Periodontics Restorative Dent* 2006; 26:215–221.
46. Rosenfeld AL, Mandelaris GA, Tardieu PB. Prosthetically directed implant placement using computer software to ensure precise placement and predictable prosthetic outcomes. Part 2: rapid-prototype medical modeling and stereolithographic drilling guides requiring bone exposure. *Int J Periodontics Restorative Dent* 2006; 26:347–353.
47. Almog DM, LaMar J, LaMar FR, LaMar F. Cone beam computerized tomography-based dental imaging for implant planning and surgical guidance, Part 1: single implant in the mandibular molar region. *J Oral Implantol* 2006; 32:77–81.
48. Mischkowski RA, Zinser MJ, Neugebauer J, Kübler AC, Zöller JE. Comparison of static and dynamic computer-assisted guidance methods in implantology. *Int J Comput Dent* 2006; 9:23–35.
49. Azari A, Nikzad S, Kabiri A. Using computer-guided implantology in flapless implant surgery of a maxilla: a clinical report. *J Oral Rehabil* 2008; 35:690–694.
50. Nikzad S, Azari A. A novel stereolithographic surgical guide template for planning treatment involving a mandibular dental implant. *J Oral Maxillofac Surg* 2008; 66:1446–1454.
51. Sherry JS, Sims LO, Balshi SF. A simple technique for immediate placement of definitive engaging custom abutments using computerized tomography and flapless guided surgery. *Quintessence Int* 2007; 38:755–762.
52. Al-Harbi SA, Sun AY. Implant placement accuracy when using stereolithographic template as a surgical guide: preliminary results. *Implant Dent* 2009; 18:46–56.